

PATIENT PRESENTING CLINICAL SIGNS

Isabelle Lawlor

History: 3/6 murmur, pre op

SPECIES ECHOCARDIOGRAPHIC FINDINGS

Feline

2D, M-mode, and Doppler study.

BREED

Left atrial size is normal. The mitral valve is normal. Left ventricular wall thickness is normal. Left ventricular dimensions are normal. Left ventricular systolic function is hyperdynamic. The aorta and aortic valve appear normal, though there is mildly increased flow velocity in the ascending aorta. Right atrial and right ventricular dimensions are normal. The tricuspid valve is normal. The pulmonary artery and pulmonic valve are normal. No shunting lesions are visualized. No pericardial effusion or cardiac masses are seen.

DSH

SEX

FS

LA - 15.0 mm

LA/Ao - 1.28

AGE

IVSd - 5.3 mm

LVPWd - 5.4 mm

8 years

LVIDd - 13.4 mm

LVIDs - 5.9 mm

WEIGHT

FS - 56%

RA - 9.9 mm

10.2#

LVOT - 1.79 m/s

RVOT - 1.38 m/s

INTERPRETED BY ASSESSMENT/RECOMMENDATIONS

Keith Blass, DVM,
MS, DACVIM

Normal echocardiogram

This examination demonstrates no evidence of structural heart disease. Isabelle's murmur appears to be due to the presence of mildly increased flow velocity in her aorta, which is a common reason for a functional/innocent murmur to develop in cats.

IMAGING PERFORMED BY

Rebekah Jakum, CVT
ARDMS/RVT

No therapy is recommended based on this exam, and there are no contraindications to the use of any specific anesthetic agents.

HOSPITAL NAME

Maple Hills VH

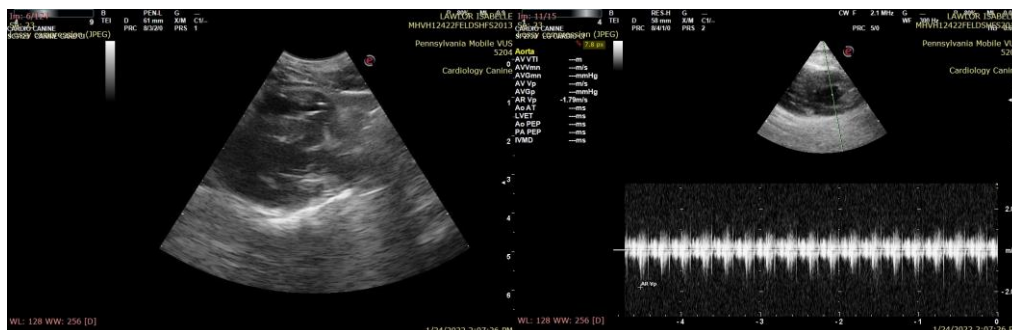
A recheck echocardiogram is recommended if the characteristics of Isabelle's murmur change, or if other new physical exam and/or clinical abnormalities suggestive of cardiac dysfunction develop.

REFERRING VET

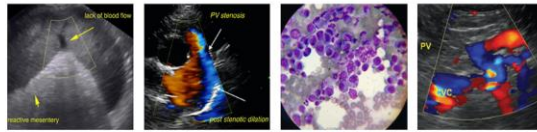
Dr. Eckman

DATE

1.24.2022



The information and recommendations provided are based on the images presented by the referring veterinarian.



PATIENT No evaluation can be communicated regarding pathology that was not visible in the image/video clips provided.

Isabelle Lawlor

SPECIES Thank you for this referral. If the clinical or image interpretation does not parallel your findings or if I can be of any further assistance please contact me.

Feline

Keith Blass, DVM, MS, DACVIM (Cardiology)

BREED KeithBlass@gmail.com

631-804-5754

DSH

SEX

FS

AGE

8 years

WEIGHT

10.2#

INTERPRETED BY

Keith Blass, DVM,
MS, DACVIM

**IMAGING
PERFORMED BY**

Rebekah Jakum, CVT
ARDMS/RVT

HOSPITAL NAME

Maple Hills VH

REFERRING VET

Dr. Eckman

DATE

1.24.2022